

Contents lists available at [ScienceDirect](http://www.sciencedirect.com)

International Journal of Surgery Case Reports

journal homepage: www.casereports.com

Periprosthetic seroma with false-positive FDG PET-CT reactive nodes mistaken for metastases in a patient previously treated of metastatic melanoma. Potential source of diagnostic errors



Alberto Gomez Portilla^{a,b,*}, Eleder Onaindia^c, Maitane Larrañaga^a,
Eduardo López de Heredia^{a,b}, Victor Echenagusía^a

^a Department of General Surgery and Digestive Diseases, University Hospital of Araba, Spain

^b University of the Basque Country, UPV, Spain

^c Department of Surgery, University of the Basque Country, UPV, Spain

ARTICLE INFO

Article history:

Received 6 June 2017

Accepted 3 July 2017

Available online 8 July 2017

ABSTRACT

INTRODUCTION: FDG PET/CT is believed to be crucial in oncology, but its limited specificity represents a challenge. Prosthetic meshes used for repair abdominal defects may lead to false-positives FDG PET/CT uptake, over staging malignancies and inducing inappropriate treatments. A false-positive FDG PET/CT uptake mimicking metastatic disease during the follow-up of a previously treated metastatic melanoma patient is presented.

© 2017 The Author(s). Published by Elsevier Ltd on behalf of IJS Publishing Group Ltd. This is an open access article under the CC BY-NC-ND license (<http://creativecommons.org/licenses/by-nc-nd/4.0/>).

Presentation of case A 36-year-old woman treated of an isolated rectus abdominis metastasis of melanoma with a compartmental resection, had her abdominal wall reconstructed with two overlapped preperitoneal polypropylene meshes. During her follow-up a periprosthetic seroma was detected on a CT Scan. The FDG PET/CT showed a periprosthetic uptake, multiple omental nodes, and an hilar mediastinal hypermetabolic foci. As initially thought to be a systemic progression of the disease, the patient was wrongly treated with Nivolumab^R. Due to undesirable side-effects of the treatment, and to diagnostic doubts about an incomplete partial response, a surgical laparoscopic omentectomy of the residual epiploic nodes was undertaken. The histologic study proved absence of malignancy.

Results The final biopsy leads to the hypothesis that these omental and mediastinal nodes were reactive to the seroma, and that the patient was erroneously treated based on a false-positive FDG PET/CT.

Conclusions Awareness of false positive FDG PET/CT secondary to periprosthetic seroma is essential. A proven positive histologic diagnosis is needed before any further treatment, in order to avoid misinterpretations, unnecessary harm, and, hence, offer an optimal treatment. This is especially mandatory for young patients with good life-expectancy and performance status.

1. Introduction

Nuclear Medicine tests have played a key-role in medical practice. Whole-body ¹⁸F-2-fluoro-2-deoxy-D-glucose positron emission tomography and computed tomography (FDG PET/CT) has achieved a powerful combination of functional and anatomical diagnoses. It is of major utility in oncology, where its sensibility and specificity makes it one of the best options for the staging and the follow-up of several tumors. FDG PET/CT has proven to be an extremely useful tool in the detection of the unpredictable metastatic spread of melanoma [1], with an overall accuracy of near 90% and above in most of tissues suitable for metastases [1]. Nevertheless, it can also result in a significant number of false-positives that should be taken into account.

False- positives in FDG PET/CT may be produced by several inflammatory and reactive processes, such as post-surgical fluid collections (including seromas, hematomas, abscesses and infections) [3]. This overlap appearance leads to the diagnostic dilemma in the differentiation of recurrence on post-operative staging of malignant neoplasms. Therefore, knowledge about the distribution of the tracer and benign pathologic causes of FDG uptake is essential for a correct interpretation of the test [6].

Although, melanoma is a tumor with a behavior that is not always predictable, there have been very few reports published of melanoma metastasizing to rectus abdominis muscle [7–9], and fewer publications of melanoma metastasizing to the omentum, which is an extremely rare site for metastasis [10–12]. As the condition is so rare, there is no consensus on the best treatment and proper chemotherapy [13]. A false-positive FDG PET/CT uptake

* Corresponding author at: C/Landázuri, 1-6^o Izquierda, 01008 Vitoria, Spain.

E-mail addresses: agomezpor@gmail.com (A. Gomez Portilla),

eleder93@gmail.com (E. Onaindia), maitanelz@hotmail.com (M. Larrañaga),

eduardmentia@gmail.com (E. López de Heredia), bittor.01@hotmail.com

(V. Echenagusía).

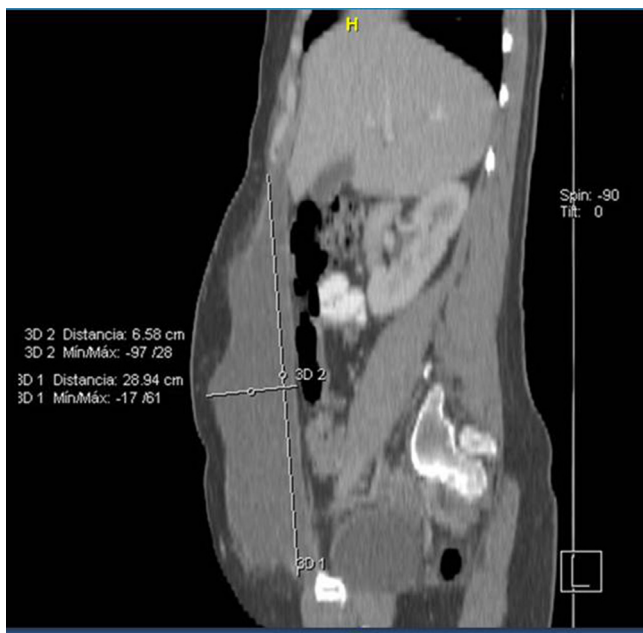

Fig. 1. Computed tomography revealed a 1-l periprosthetic seroma.

mimicking metastatic disease during the follow-up of a previously metastatic melanoma patient treated in the University Hospital of Araba is presented.

This work has been reported in line with the SCARE criteria [14].

2. Presentation of case

A 36-year-old woman had been previously treated by our team in the University Hospital of Araba of an isolated right rectus abdominis metastasis from melanoma in December 2015. She underwent a widely radical compartmental resection of her right rectus abdominis muscle and her abdominal wall was reconstructed with two overlapped preperitoneal polypropylene meshes. The patient did well, but in January 2016 she noted a fluctuant abdominal mass. A CT Scan showed a huge periprosthetic seroma of 1 l (Fig. 1). The periprosthetic seroma resolved spontaneously. Two months later, a combined FDG PET/CT was performed for re-staging. High FDG periprosthetic uptake with multiple omental nodes and an hilar mediastinal hypermetabolic foci were found, with a maximum standardized uptake value (SUV_{max}) of 4.22 and 6.22 for the omental and mediastinal foci respectively (Fig. 2). These FDG PET/CT findings were first thought almost certainly

to be a systemic progression of the disease, and the patient was wrongly treated with Nivolumab[®]. Our patient suffered gastrointestinal undesirable side-effects with the treatment. This fact, along with diagnostic doubts about an incomplete partial response, with disappearance only of the mediastinal node, led us to perform a laparoscopic omentectomy of the residual epiploic nodes. No other lesions were identified into the abdomino-pelvic cavity. The histologic examination yielded a final diagnosis of absence of malignancy, with reactive phenomena. Nine months after this last surgery, the patient remains well with no evidence of recurrence.

3. Discussion

Patients with metastatic melanoma have a high risk for recurrence and metastases. The treatment of metastatic melanoma continues to be challenging. Systemic therapy is the mainstay of treatment for most patients. Limited burden of disease do best with surgical treatment. Cases of omental metastases of melanoma are extremely unusual in the literature [10–12]. Either complete surgical resection or chemotherapy should be chosen as option treatments in such uncommon patients.

FDG PET/CT has proven to be an extremely useful tool in the detection of melanoma metastases [1]. Pfanenberg et al. [2] attribute an 89% specificity of the FDG PET/CT for the study of lymph nodes metastases of melanoma. Nevertheless, the SUV_{max} threshold should be interpreted with caution for diagnosing and treating lesions, since still there are numerous false positives non-tumoral conditions in the literature reporting this unresolved problem [4–6,15–19]. This situation can cause misinterpretations in reading FDG PET/CT images. It may affect the decision making process, and, as a consequence, may lead to prescribe inappropriate treatments.

Our patient presented a huge post-surgical periprosthetic seroma with spontaneous resoluteness. These postoperative fluid collections have been included between the benign pathologies that might show false-positive uptakes on FDG PET/CT [3]. Her omental nodes hypermetabolic foci detected had only a SUV_{max} of 4.22, which is not an absolute discriminative value for determining the malignant nature of those lesions. This overlap in imaging appearance leads to diagnostic dilemmas. Omentum is known to play a protective role in isolating inflammation in intra-abdominal diseases [20]. The rarity of our patient's scenario, with a postoperative periprosthetic seroma, multiple omental nodes, and an hilar mediastinal soft hypermetabolic foci, could be an argument against the malignant nature of these findings. But, since our patient had been previously treated of an isolated metastasis to the rectus abdominis [9], and the values detected on the FDG PET/CT were borderline, it was erroneously assumed that she was suffering an

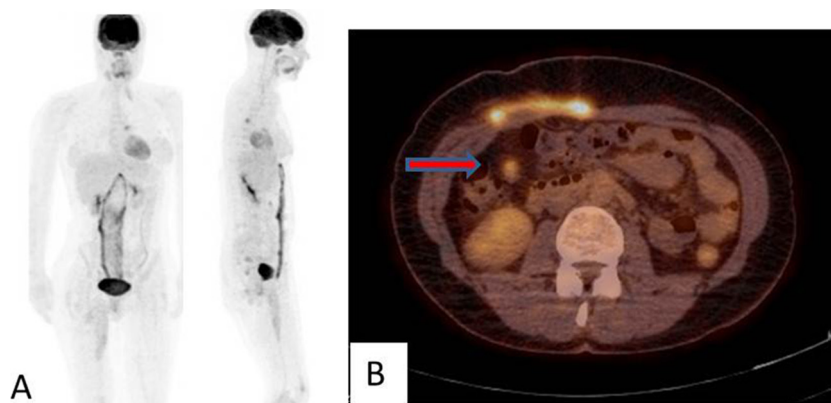


Fig. 2. A) Coronal FDG PET image showing the periprosthetic seroma uptake multiple omental nodes and an hilar mediastinal hypermetabolic foci. B) Axial section of the hybrid fused FDG PET-CT. The red arrow is pointing to a small round lesion in the right upper quadrant, most likely representing omental lesions.

abdominal and mediastinal progression of the disease. The presence of these bicompartimental metastases contraindicated any aggressive surgical excision at that time, and accordingly, she was mistreated with new adjuvant chemotherapy again.

Probably, a more resolute approach should have been considered in order to grant a diagnosis of certainty, offer the right therapeutic choice, and thus, minimize morbidity.

The appearance of severe colitis as an undesirable side-effect to the treatment, together with an incomplete partial response to the treatment, translate into the disappearance of the mediastinal hilar node, which initially was the main contraindication for surgery, made us reconsider a surgical tentative. Lastly, our patient underwent a laparoscopic omentectomy of the residual epiploic nodes and the histologic study of the specimen definitely cleared the diagnostic doubts with a final diagnosis outcome of absence of malignancy.

4. Conclusions

FDG PET-CT is a sensitive modality for the differentiation of malignancy. However, the awareness of possible false-positives secondary to postoperative periprosthetic seroma, mainly due to inflammation, is vital in order to avoid misinterpretation of the FDG PET-CT imaging and to guarantee the most appropriate treatment. Knowledge of these conditions is essential in patients previously treated for malignant metastatic diseases, as accurate staging of the extent of disease is extremely important for an appropriate treatment plan, in order to minimize morbidity and maximize survival.

In addition to clinical data, a proven histologic diagnosis of certainty before any further adjuvant treatment is needed to guarantee an optimal treatment and, hence to avoid unnecessary harm. As our case demonstrates, this is especially mandatory for young patients with good life-expectancy and performance status.

Conflict of interest

None.

Sources of funding

None.

Ethical approval

Nothing to declare.

Consent

Written informed consent was obtained from the patient for publication of this case report and accompanying images. A copy of the written consent is available for review by the Editor-in-Chief of this journal on request.

Author contribution

All the Authors have contributed on the study design, data analysis, and writing the paper.

All authors (A Gómez Portilla, E Onaindia, M Larrañaga, E López de Heredia, V Echenagusía), have approved the submission of this article for publication.

Guarantor

Alberto Gómez Portilla.

References

- [1] W.D. Holder, R.L. White, J.H. Zuger, E.J. Easton Jr., F.L. Greene, Effectiveness of positron emission tomography for the detection of melanoma metastases, *Ann. Surg.* 227 (1998) 764–771.
- [2] C. Pfannenber, P. Aschoff, S. Schanz, S. Eschmann, C. Plathow, T.K. Eigentler, et al., Prospective comparison of ¹⁸F-fluorodeoxyglucose positron emission tomography and whole body magnetic resonance in staging of advanced malignant melanoma, *Eur. J. Cancer* 43 (2007) 557–564.
- [3] B. Amini, J.E. Madewell, H.H. Chuang, T.M. Haygood, B.P. Hobbs, P.S. Fox, et al., Differentiation of benign fluid collections from soft-tissue sarcomas on FDG-PET/CT, *J. Cancer* 5 (2014) 328–335.
- [4] R. Drescher, M. Freesmeyer, PET/US fusion as a problem-solving tool in oncology imaging: differentiation of hernia repair mesh plugs from malignancy suspected on PET/CT, *Clin. Nucl. Med.* 39 (2014) 75–77.
- [5] N.M. Long, C.S. Smith, Causes and imaging features of false positives and false negatives on ¹⁸F-PET/CT in oncologic imaging, *Insights Imaging* 2 (2011) 679–698.
- [6] P.D. Shreve, Y. Anzai, R.L. Wahl, Pitfalls in oncologic diagnosis with FDG PET imaging: physiologic and benign variants, *Radiographics* 19 (1999) 61–77.
- [7] K. Namikawa, N. Yamazaki, Metastatic melanoma on the abdominal wall image of the month, *Jpn. J. Clin. Oncol.* 39 (2009) 33.
- [8] A. Hichem, R. Saber, M. Bassem, D. Alifa, R.M. Lamia, Z. Ayoub, Mélanome du muscle droit de l'abdomen: à propos d'un cas, *La Tunis. Med.* 92 (2014) 432–433.
- [9] A. Gomez Portilla, A. Cruz, N. Juan, P. Malo, E. López de Heredia, M. Larrañaga, Isolated rectus abdominis metastasis from melanoma- An extremely rare case, *Int. J. Surg. Case Rep.* 26 (2016) 121–123.
- [10] H. Zhao, M. Yang, X. Zhang, S. Zhao, G. Yao, Y. Wang, et al., The first case of omental metastasis from choroidal melanoma, *Jpn. J. Clin. Oncol.* 43 (2013) 314–317.
- [11] C. Halkias, J. Sloane, M. Ben-Gashir, G. Bashir, Synchronous metastatic omental melanoma and colonic adenocarcinoma: a case report, *BMC Res. Notes* 8 (2015) 125.
- [12] M. Stryga, M. Janas, P. Szopinski, Melanoma metastases to the small intestine mesentery, greater omentum and parietal peritoneum—case report, *Pol. Przegl. Chir.* 81 (2009) 203–207.
- [13] A.S. Caudle, M.I. Ross, Metastectomy for stage IV melanoma: for whom and how much, *Surg. Oncol. Clin. N. Am.* 20 (2011) 133–144.
- [14] R.A. Agha, A.J. Fowler, A. Saetta, I. Barai, S. Rajmohan, D.P. Orgill, for the SCARE Group, The SCARE statement: consensus-based surgical case report guidelines, *Int. J. Surg.* 34 (2016) 180–186.
- [15] G.C. Mackie, J.M. Pohlen, Mediastinal histoplasmosis: F-18 FDG PET and CT findings simulating malignant disease, *Clin. Nucl. Med.* 30 (2005) 633–635.
- [16] D. Kalkanis, A. Kalkanis, O. Goma, F.M. Paes, G.N. Sfakianakis, F-18 FDG PET positive hilar and mediastinal lymphadenopathy mimicking metastatic disease in a melanoma patient treated with interferon-alpha-2b, *Clin. Nucl. Med.* 36 (2011) 154–155.
- [17] K. Ivanova, K. Glatz, A. Zippelius, G. Nicolas, P. Itin, Acute toxoplasmosis mimicking melanoma metastases: review of conditions causing false-Positive results on ¹⁸F-FDG PET/CT, *Dermatology* 225 (2015) 349–353.
- [18] G. Chassagnon, G. Metrard, H. Besse, S. Gauvain, ¹⁸F-FDG PET imaging in a patient with late omental infarction after treatment of pancreatic adenocarcinoma, *Clin. Nucl. Med.* 39 (2014) 567–569.
- [19] P. Castellucci, C. Nanni, M. Farsad, L. Alinari, P.L. Zinzani, V. Stefoni, et al., Potential pitfalls of ¹⁸F-FDG PET in a large series of patients treated for malignant lymphoma: prevalence and scan interpretation, *Nucl. Med. Commun.* 26 (2005) 689–694.
- [20] D. Collins, A.M. Hogan, D. O'Shea, D.C. Winter, The omentum: anatomical, metabolic, and surgical aspects, *J. Gastrointest. Surg.* 13 (2009) 1138–1146.

Open Access

This article is published Open Access at sciedirect.com. It is distributed under the [IJSCR Supplemental terms and conditions](#), which permits unrestricted non commercial use, distribution, and reproduction in any medium, provided the original authors and source are credited.